

## Clinical case

# Cystic duplication as a rare congenital anomaly of the gastrointestinal tract in children

Jamoliddin B.Sattarov <sup>1</sup> , Marufjon Sh.Boboev <sup>\*2</sup> , Nodirjon S.Khaidarov <sup>3</sup><sup>1</sup> Department of Urology, Tashkent State Medical University, Tashkent, 100109, Uzbekistan<sup>2</sup> Tashkent City Children's Clinical Surgical Hospital No. 2, Tashkent State Medical University, Tashkent, 100109, Uzbekistan<sup>3</sup> Department of General Surgery, Fergana Institute of Public Health, Fergana, 150100, Uzbekistan

dr.jamol\_83@mail.ru (J.S.), boboyev.m.s@tashmeduni.uz (M.B.), nodirxaydarov6@gmail.com (N.Kh.)

\* Correspondence: boboyev.m.s@tashmeduni.uz (M.B.)

**Abstract:** Case: A 1-year-old female patient presented for the workup of a cystic abdominal lesion that was first discovered at 6 to 7 months of life. A first CT scan of the abdomen and retroperitoneal space showed a cystic mass localized nearby the left adrenal gland. Based on these results the patient was referred to our clinic. An abdominal multislice computed tomography (MSCT) was performed later, which could separate the diagnoses of splenic cyst and gastric duplication cyst. On serial ultrasound examinations, the lesion progressively increased in size, and surgical management was undertaken. Histopathological examination confirmed the diagnosis of gastric duplication.

**Conclusion.** The multimodal diagnostic approach allows early identification of this rare pathology, aids the differential diagnosis in atypical gastric duplication localization cases and allows to determine indications for surgical treatment.

**Keyword:** Stomach duplication, children, surgical treatment.

## Introduction

**Relevance.** Duplications of gastrointestinal tract (DGT) is a rare form of congenital anomaly in which duplication closely associated with adjacent segment of GIT, exhibiting both an epithelial lining compatible with the digestive mucosa and a well-developed smooth muscle layer. It is estimated that 1 in 4,500 live births present with DGT [1,4,5,9].

Most gastrointestinal duplications are diagnosed by the age of two. Both sexes are affected, but most series show a slight male predominance. Note: Learn how to reduce the klincl definition in insufficient registrations Congenital gastric malformations are a heterogeneous group of disorders, characterized by variable topographic and anatomical variants [12].

Gastric duplications are classified as complete and incomplete (cystic or diverticular) as well as according to their communication with the gastric lumen (communicating or non-communicating). This localization is rare, constituting 3.8–7 % of all gastrointestinal duplications [2,4,10]. It is important to note that, contrary to findings in duplications at other sites, gastric duplications are primarily diagnosed in women.

The duplicated segment usually has a common muscle wall and blood supply to the native stomach, and in rare cases communicates directly with the gastric lumen. At most times, duplication presents as a cystic mass communicating with the greater curvature or located in antral part filled with mucous or serous-fluid. The cyst wall can have a lining of gastric, jejunal, ileal or colonic mucosa. Approximately 10% of the cases are associated with ectopic pancreatic tissue on an etiology basis. The fact that these cysts contain gastric mucosa which can secrete hydrochloric acid and pepsin causes them to be at risk for inflammatory change and ulceration [1,2,6,11].

There are four recognized criteria for the diagnosis of cystic gastric duplication, which are as follows:

An internal lining of epithelial tissue as is characterized in the digestive tract;

An outer smooth muscle layer;

**Quoting:** Jamoliddin B.Sattarov, Marufjon Sh.Boboev, Nodirjon S.Khaidarov. Cystic duplication as a rare congenital anomaly of the gastrointestinal tract in children. 2026, 5, 1, 2. <https://doi.org/10.56121/MSU-2026-1-00002>

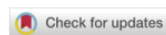Received: 29.12.2025

Corrected: 18.01.2026

Accepted: 25.02.2026

Published: 27.02.2026

Copyright:



Gastric vessels: Supplies blood to the gastric plates.

Anatomical continuity with the stomach, such that the cyst is a true extension of gastric wall [3].

Early radical surgical excision of the lesion is the treatment of choice for gastrointestinal duplications. The complete resection lowers the risk of complications and late development of cancer. This helps to avoid inflammatory sequelae along with perforation linked with these lesions [1,7].

Surgeons need to carefully analyze the specific anatomy of the duplication and be well-versed in potential surgical approaches. In some clinical conditions, radical surgical excision may incur substantial risk; alternative interventions include mucosectomy or fenestration. Serious late complications related to incomplete excision may include: recurrence of cystic duplication, persistent inflammation and in neuroenteric duplications meningitis, gastrointestinal hemorrhage, and perforation [8,13].

**Objective of this study:** To show the diagnostic significance and treatment options for duplication anomalies of the gastrointestinal tract using a clinical case.

## Materials and Methods

The basis of this study is that clinical records, instrumental diagnostics, and histological examination data was analyzed at a children's department of Tashkent City Clinical Hospital No2.

This report presents a rare gastric anomaly, non-communicating cystic duplication of stomach and describes its diagnostic and surgical management.

## Results

Seventeen clinical cases of cystic duplication of the gastrointestinal tract are presented, two of which were duplicate stomachs, which is an extremely rare location for this type of deformity to occur among gastrointestinal duplications.

There were significant challenges with the diagnosis of gastric duplication as both the anatomic location of the lesion was atypical and there were no pathognomonic clinical findings. Ultrasound was the first line imaging modality in these situations and it always detected a large cystic structure in abdomen. Despite this, ultrasound characteristics were often without specificity to ultimately determine the organ of origin in consensus.

The onset of computed tomography (CT) and multislice computed tomography (MSCT) of the abdominal organs greatly improves diagnostic accuracy by producing images with very high resolution that show exactly how a given lesion is related to surrounding anatomical structures. These findings did not eliminate the need for differential diagnosis especially to differentiate between gastric duplication cysts vs. other cystic lesions of spleen, adrenal glands and other intra-abdominal masses despite these progresses in imaging techniques.

The definite diagnosis of gastric duplication was made after surgical resection and histopathological examination of the excised specimen. Surgical treatment (i.e., radical excision of the cystic duplication) allowed a complete removal of the pathological tissue and prevented future potential complications.

This clinical series underscores the benefit of a multimodal diagnostic approach combining ultrasound, CT imaging and morphological confirmation. This approach allows identification of rare gastric duplication cysts safely and in an accurate manner, thereby enabling judicious decision-making with respect to surgical intervention.

**Introduction** A 1-year-old female, Patient A., was referred to the Elective Surgery Department of Tashkent City Clinical Hospital No. 2 with epigastric pain and recurrent febrile episodes. **Abstract:** Her past medical history was significant for epigastric pain that started around 6 to 7 months of age. Ultrasonography at a local primary care clinic first identified a cystic mass confined to the left adrenal region. The patient was then transferred to our institute as the same abdominal and retroperitoneal CT scans showed a cystic lesion of the left adrenal gland. At the time of admission, the patient was acutely asymptomatic, and her physical examination was unremarkable.

The test was carried out at ultrasound department. The liver showed normal size and architecture. No abnormalities were identified within gallbladder, which was homogeneous in appearance. The main bile duct was 0.3 cm in diameter, and the portal vein measured 0.5 cm (both normal). No structural changes were detected in the pancreas or kidneys. Spleen was 8×3.5 cm with normal

echogenicity However, the lower pole of the spleen showed a 4.4 x 3.5 cm hybrid cystic and cavity-like formation. No abdominal compartment showed enlargement of the retroperitoneal lymph nodes.

**Table 1.** Results of laboratory and hormonal tests of the patient.

Indicator	Meaning	Units of measurement	Reference values
<b>Complete blood count</b>			
Hemoglobin (Hb)	113	g/l	110–140
Red blood cells (RBCs)	5.06	$\times 10^{12}/l$	3.8–5.3
Leukocytes (Leu)	5.1	$\times 10^9/l$	5.0–12.0
Platelets (T/r)	184	$\times 10^9/l$	180–400
ESR	5	mm/h	2–10
Reticulocytes	2	%	2–10
Band neutrophils	1	%	1–5
Segmented neutrophils	46	%	32–55
Eosinophils	1	%	1–5
Lymphocytes	45	%	35–60
Monocytes	7	%	3–10
<b>Blood biochemistry test</b>			
Blood amylase	8	U/L	25–125
Total protein	50.8	g/l	60–80
Blood glucose	4.4	mmol/L	3.3–5.5
Total bilirubin	11.6	$\mu\text{mol}/L$	5–21
Urea	5.4	mmol/L	1.8–6.4
Residual nitrogen	21.5	mmol/L	14.3–28.6
Creatinine	94	$\mu\text{mol}/L$	27–88
AST	0.2	mmol/ml	up to 0.45
ALT	0.2	mmol/ml	up to 0.45
<b>Hormonal indicators (examination by an endocrinologist)</b>			
Alpha-amylase	48	U/L	28–100
Glucose	4.7	mmol/L	3.3–5.5
ACTH	29.3	ng/ml	up to 50
Cortisol	421.7	nmol/L	260–720
<b>Blood group</b>			
Blood group	0 (I)	—	—
Rh factor	Positive	—	—

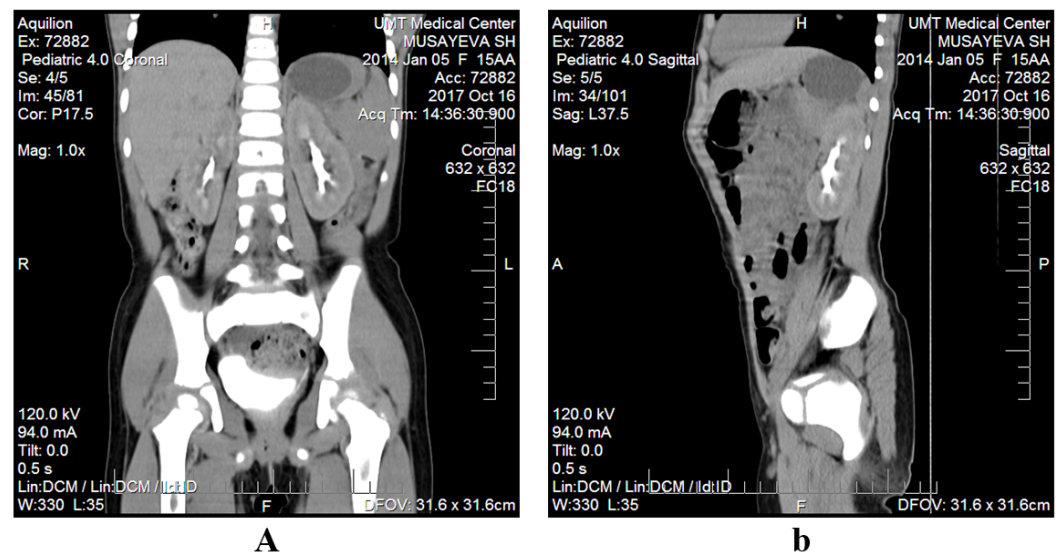
Biochemical evaluations by endocrinologist showed the following: alpha-aminoglycosidase 48 U/L (reference range 28–100 U/L), blood glucose level 4.7 mmol/L, adrenocorticotrophic hormone (ACTH) 29.3 ng/mL (normal values up to 50 ng/mL), and serum cortisol 421.7 nmol/L (normal range 260–720 nmol/L). This were in agreement with the diagnosis of a cystic lesion located within the adrenal vein.

Neuroblastoma assessment by a pediatric oncologist suggested that measurement of neuron-specific enolase (NSE) was elevated at 22.67 ng/mL (normal upper limit, 13.2 ng/mL). Based on the clinical presentation combined with laboratory and imaging findings, a provisional diagnosis of pancreatic cyst was made.

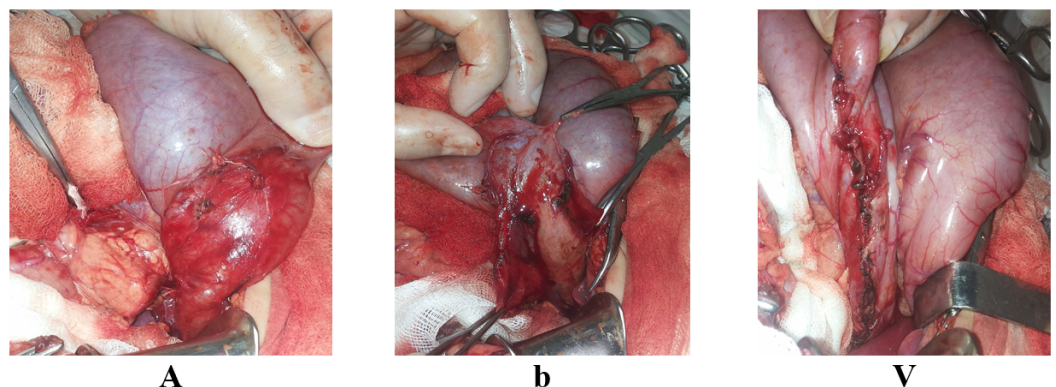
Surgical intervention entailed a laparotomy. At laparotomy, after exploration of the abdominal cavity posterior to the stomach's fundus and body were observed cystic structures measuring 3.0 × 4.0 × 5.0 cm in size. The Fse cysts were adherent to the gastric wall (Fig. 2. a). Superiorly, they were contiguous with the left dome of the diaphragm; laterally, they abutted against the splenic hilum and vascular structures; and inferiorly, they were adjacent to the pancreatic tail.

(MSCT) of the abdomen with excretory urography showed a left-sided 4.0×4.9×3.9cm cystic lesion between the diaphragmatic dome and proximal stomach with spleen at its postero-inferior margin. Spleen: A congenitally abnormal horseshoe spleen There were no structural abnormalities

found in the internal organs of the abdomen. Also, no associated lymphadenopathy or bone-destructive lesions were observed (Fig. 1 a, b). Final Impression: Cystic formations in the projection of left adrenal gland.



**Figure 1.** Explanation in the text



**Figure 2.** Explanation in the text

The cyst lumen was filled with a semi-fluid, pale yellow substance associated with white particulate material (Fig. 2. b). The wall of the cyst associated with the serous membrane and muscular layer of the gastric wall. It revealed no communication between the cyst and the gastric lumen. The surgical procedure involved excision of the cyst contained within the muscle layer of the stomach. The denuded gastric wall was closed using separate sutures after cyst removal (Fig. 2. c).

This cyst wall showed a multilayered architecture mimicking the structure of the abdominal gastric wall, and it contained a distinct muscularis layer. There was hypoplastic mucosal membrane with focal pathological changes.

Combining clinical findings with histopathology established a diagnosis of gastric cystic duplication.

The wound healed by primary intention after the surgery. On 9th post operative day, for removal of sutures Exploration of the abdominal cavity by an ultrasound showed no abnormalities. The patient was discharged in stable condition on the tenth day. The patient was asymptomatic on the six-month follow up. There were no abnormal findings on subsequent CT scanning.

This clinical case is interesting because gastric duplication is rare and it can be difficult to diagnose. Even with the available preoperative imaging (ultrasound and MSCT), the diagnosis and definitive organ of origin of the lesion could only be accurately diagnosed at intraoperative exploration coupled with histological analysis.

## Conclusions

1. Background Gastric duplication is a diagnostically difficult entity due to its rarity, heterogeneous clinical presentation and absence of pathognomonic symptoms which can lead to delayed diagnosis.
2. Highly advanced imaging modalities have supplied important information, but they are not useful in the differentiation of gastric duplication from other abnormal cystic abdominal lesions because of their atypical locations when attempted in preoperative recognition (such as detection using multislice computed tomography and magnetic resonance imaging).
3. Current non-invasive diagnostic methods cannot reliably characterize the mucosal lining or detect ectopic tissue, limiting the ability to conduct accurate pre-operative surgical planning.
4. The preferred treatment is complete surgical excision of the gastric duplication cyst, though relationships with the surrounding gastric wall may make radical resection technically more difficult and be at risk for iatrogenic injury.
5. Doubling cyst complete excision with careful assessment of the mucosal covering is critical considering an increased recurrence risk and late complications associated with partial resection, necessitating tailored surgical strategies and histopathological confirmation.
6. Due to the lack of cases reported, multicenter studies and standardized diagnostic and therapeutic protocols should be developed to improve outcomes for patients with gastric duplication.

## Authors' contribution

Conceptualization, J.S. and M.B.; methodology, M.B. and N.Kh.; validation, J.S., M.B. and N.Kh.; formal analysis, N.Kh.; investigation, J.S. and M.B.; resources, M.B.; data curation, J.S. and M.B.; writing—original draft preparation, J.S. and N.Kh.; writing—review and editing, M.B.; visualization, J.S.; supervision, M.B.; project administration, M.B. All authors have read and agreed to the published version of the manuscript.

## Funding source

This research received no external funding.

## Ethics approval

The study was conducted in accordance with the Declaration of Helsinki. Ethical review and approval were waived for this study due to its retrospective case report design based on anonymized clinical data without intervention.

## Consent for publication.

Written informed consent was obtained from the patient's legal guardian for publication of this case report and any accompanying images.

## Data Availability Statement

The data supporting the findings of this study are available within the article. Additional clinical data are not publicly available due to privacy and ethical restrictions but may be provided by the corresponding author upon reasonable request.

## Acknowledgments

The authors would like to express their sincere gratitude to the medical staff of Tashkent City Children's Clinical Surgical Hospital No. 2 for their assistance in the diagnosis, surgical management, and postoperative care of the patient. We also thank the Department of Urology of Tashkent State Medical University and the Department of General Surgery of the Fergana Institute of Public Health for their academic and clinical support.

## Conflict of interest

The authors declare no conflicts of interest.

## Abbreviations

DGT	Duplication of the Gastrointestinal Tract
CT	Computed Tomography
MSCT	Multislice Computed Tomography

US	Ultrasound
ACTH	Adrenocorticotrophic Hormone
NSE	Neuron-Specific Enolase
GIT	Gastrointestinal Tract

### References

- [1] Ashcraft K.W., Holder T.M. Pediatric surgery. - St. Petersburg: ICHP "Hardford", 1996. - T. 1. - P. 329.
- [2] Bataev S.Kh.M., Pupyshev M.L., Ryndin V.D. Duplication cyst of the stomach in a 3-year-old child. Surgery. Journal im. N.I. Pirogov. 2013; 9: 63–6.
- [3] Zhurilo I.P., Fomenko S.A., Litovka V.K., Perunsky V.P., Lyupinov P.A., Tunkin A.Yu. Rare variants of duplication of the digestive tract in children. Bulletin of emergency and restorative medicine. 2018; 2; 177 – 82.
- [4] Razumovsky A. Yu., Smirnov A. N., Kholostova V. V., Gavrilenko N. V. Diagnostics and surgical treatment of stomach duplications in children // Pediatric surgery. 2018; 22 (2). P. 61-64. DOI: <http://dx.doi.org/10.18821/1560-9510-2018-22-2-61-64>
- [5] Smirnov A.N., Gavrilenko N.V. Duplications of the gastrointestinal tract in children // Pediatric surgery. 2018; 22(6). P.309-316. DOI: <http://dx.doi.org/10.18821/1560-9510-2018-22-6-309-316>
- [6] Sokolov Yu.Yu., Zykin A.P., Donskoy D.V., Olkhova E.B., Tumanyan G.T., Shuvalov M.E., Khaspekov D.V., Timokhovich E.V., Leonidov A.L., Antonov D.V. Diagnostics and surgical correction of gastrointestinal tract duplications in children. Pediatric surgery. 2017; 21(3): 121–7.
- [7] Stashuk G.A., Gaganov L.E., Pykhteev D.A., Buzmakov A.A. Cystic duplication of the jejunum. Bulletin of Roentgenology and Radiology. 2015; 4: 35–9.
- [8] Abdalkader M., Al Hassan S., Taha A. Complicated Gastric Duplication Cyst in an Adult Patient: Uncommon presentation of an uncommon discomfort. J Radiol Case Rep. 2017; Aug; 11(8): 16–23.
- [9] Di Serafino M., Mercogliano C., Vallone G. Ultrasound evaluation of the enteric duplication cyst: the gut signature. J Ultrasound. 2015; Nov. 23; 19(2): 131-3.
- [10] Mayer JP, Bettolli M. Alimentary tract duplications in newborns and children: Diagnostic aspects and the role of laparoscopic treatment. World J. Gastroenterol. 2014; 20(39): 14263–71. doi: 10.3748/wjg.v20.i39.14263
- [11] Maria-Andreea Racean, Laura Mihaela Suciuc, Radu Alexandru Prisca, Cristina Oana Marginean. Diagnosis of a rare case of neonatal intestinal duplication cyst isolated from the gastrointestinal tract - Case report// Romanian Medical Journal – Volume 70, No.2, 2023. P.89-94.
- [12] Rattan KN, Bansal S., Dhamija A. Gastrointestinal Duplication Presenting as Neonatal Intestinal Obstruction: An Experience of 15 Years at Tertiary Care Center. J Neonatal Surg.2017; Jan 1; 6(1):5.
- [13] Sumiti Gupta, Vibhav Goel, Mahak Dahiya, Anjali Bishlay, Sunita Singh, Pardeep Kajal. Isolated Enteric Duplication Cyst: A Rare Congenital Anomaly // International Journal of Health Sciences and Research.137 Volume 14; Issue: 2; 2024. P.137-142.

**Disclaimer of liability/Publisher’s Note:** The statements, opinions and data contained in all publications belong exclusively to individuals. The authors and participants, and the editors. The journal and the editors are not responsible for any damage caused to people or property resulting from any ideas, methods, instructions or products mentioned in the content.